

Options in Pterygium surgery



Stanila Adriana **, Ionut Costache*, Dan Stanila **

Emergency Hospital Sibiu *

Faculty of Medicine "V. Papilian" University Lucian Blaga Sibiu **

Ocular Surface Research Center Sibiu

Pterygia (πτερυγα - *greek*) = wing

- A pterygium is an elevated, superficial, external ocular mass that usually forms over the perilimbal conjunctiva and extends onto the corneal surface
- Pterygia can vary from small, atrophic quiescent lesions to large, aggressive, rapidly growing fibrovascular lesions that can distort the corneal topography, and, in advanced cases can cover the optical center of the cornea
- Pterygium is one of the oldest ocular diseases known
- The etiology and the treatment of pterygium are still discussed and uncertain. The rate of recurrence is high

Etiology

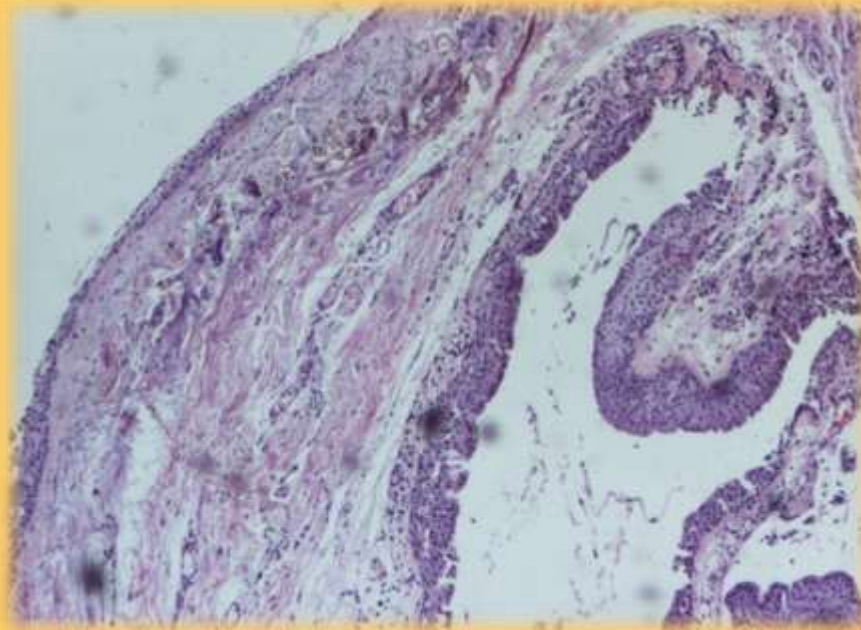
- Risk factors for pterygium include the following:
 - Increased exposure to ultraviolet light, including living in subtropical and tropical climates
 - Engaging in occupations that require outdoor activities
- A genetic predisposition to the development of pterygia appears to exist in certain families
- A predilection exists for males to develop this condition in significantly higher numbers than females, although this finding may represent an increased exposure to ultraviolet light in this portion of the population

Prevalence

- There is a relationship between increased prevalence and elevated levels of ultraviolet light exposure
- It is uncommon for patients to present with pterygia up to the age of 20 years
- Patients older than 40 years have the highest prevalence of pterygia
- Patients aged 20-40 years are reported to have the highest incidence of pterygia.

PATHOPHYSIOLOGY

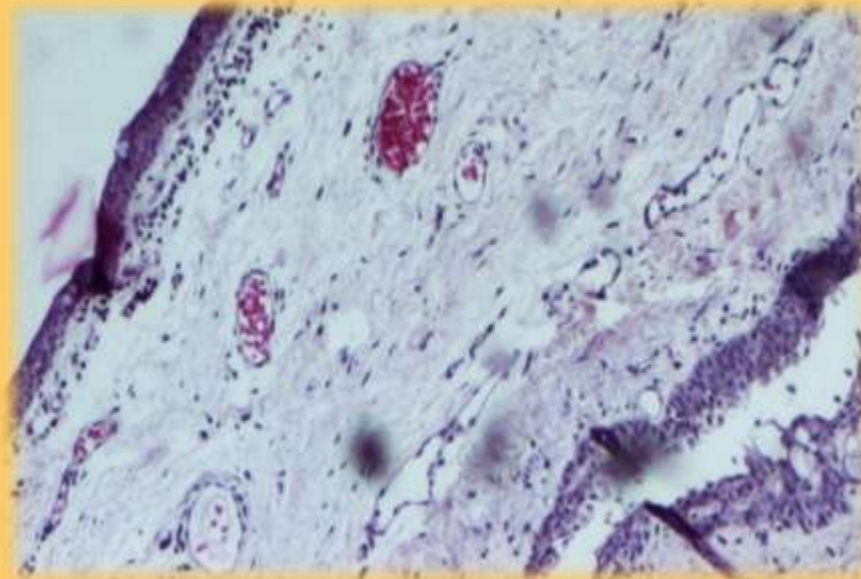
- The pathophysiology of pterygia is characterized by elastotic degeneration of collagen and fibrovascular proliferation, with an overlying covering of epithelium.



Anatomo-pathological aspect

Histopathology

- Histopathology of the abnormal collagen in the area of elastotic degeneration shows basophilia with hematoxylin and eosin stain. This tissue also stains with elastic tissue stains, but it is not true elastic tissue, because it is not digested by elastase.



Anatomo-pathological aspect

AIM OF STUDY

- This study intends to reveal the best operating protocol for managing the primary pterygium and the recurrences in order to obtain rapid healing, transparent corneas and no recurrences.
- The optimum mode of treatment for symptomatic pterygium would combine efficacy (a low recurrence rate) with safety (freedom from sight threatening complications)

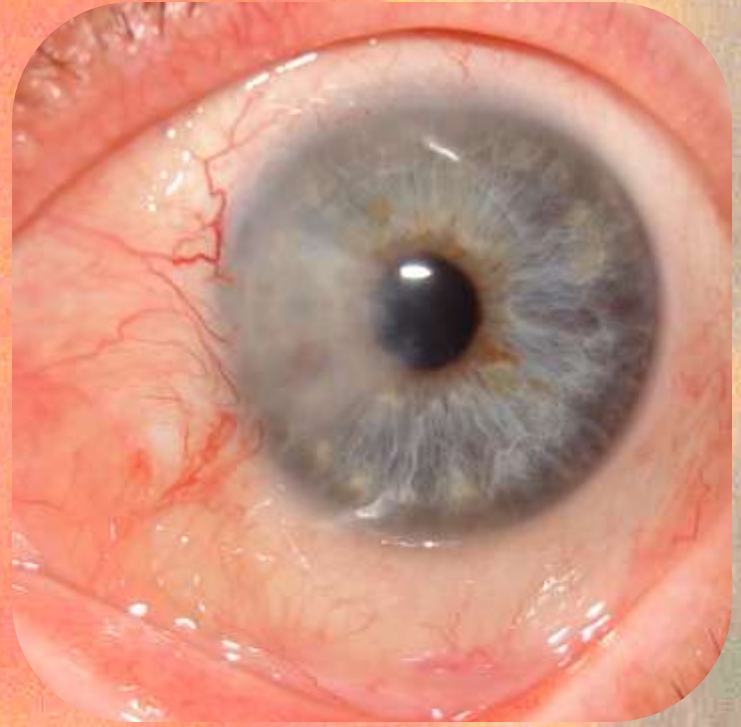
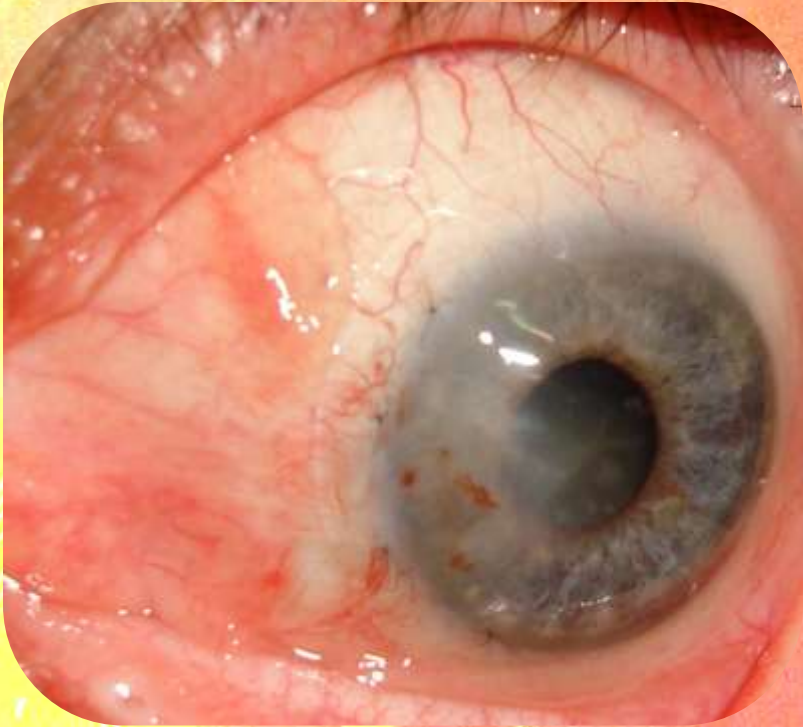
MATERIAL, METHOD

- We studied 81 cases of pterygium operated using different methods, according to the clinic form. In all cases we applied a therapeutic contact lens after the removal of the pterygium. In large pterygiums and in recidives we also did an amniotic membrane transplant. The use of amniotic membrane transplantation (AMT) is safe, effective, and may be employed in conjunction with other techniques. In some cases we used also avastin.**

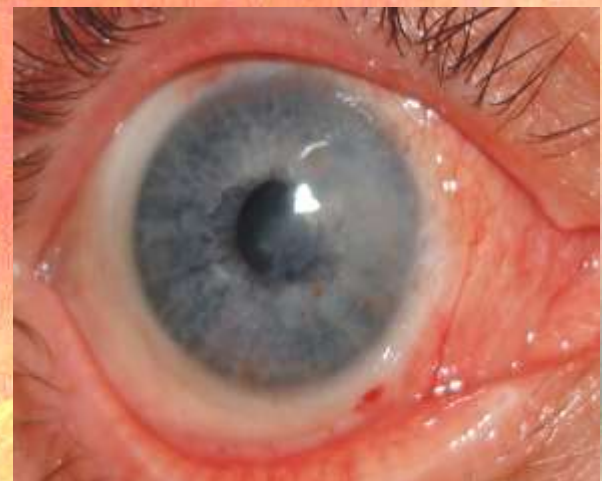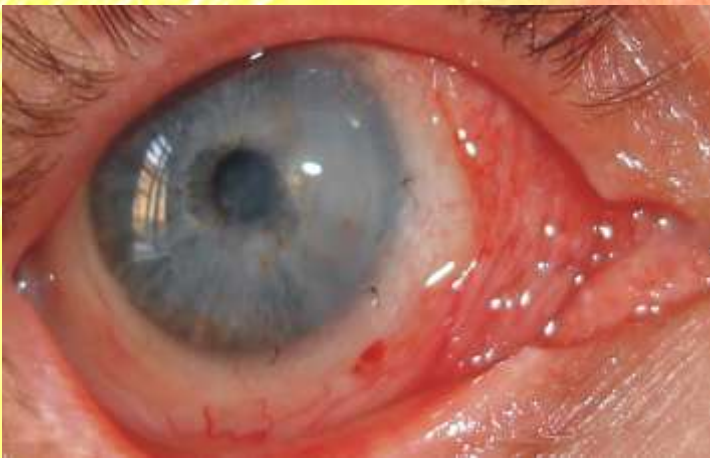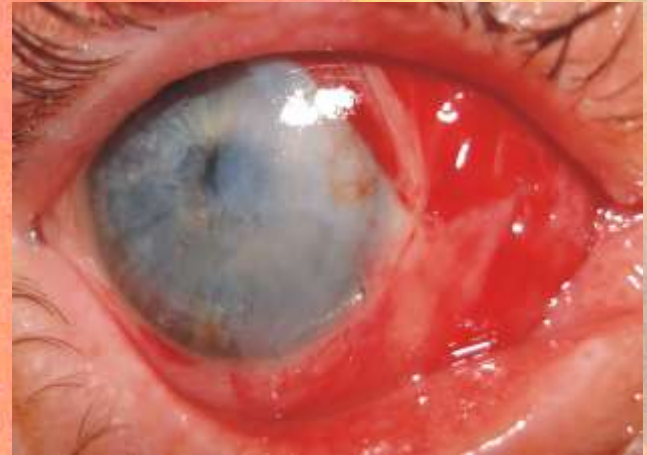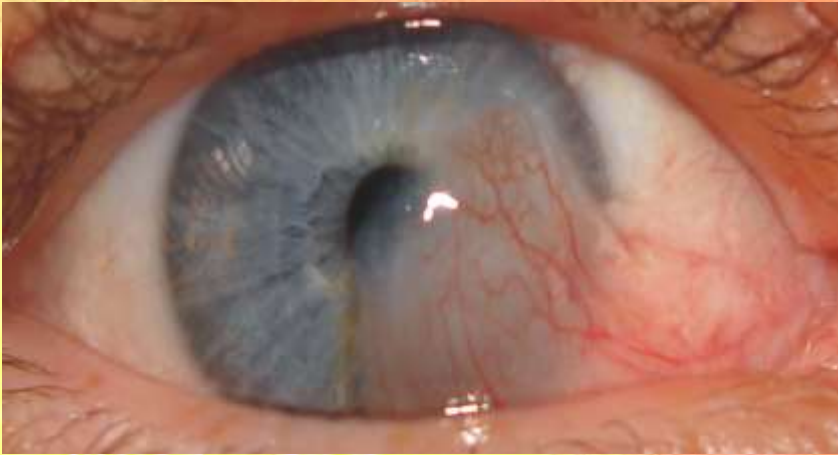RESULTS, DISCUSSIONS

- The evolution was encouraging in all cases. The healing of the cornea was rapid with minimum pain. The aspect of the cornea was satisfying. We had only five recurrences, 6%.**
- We present several suggestive cases.**

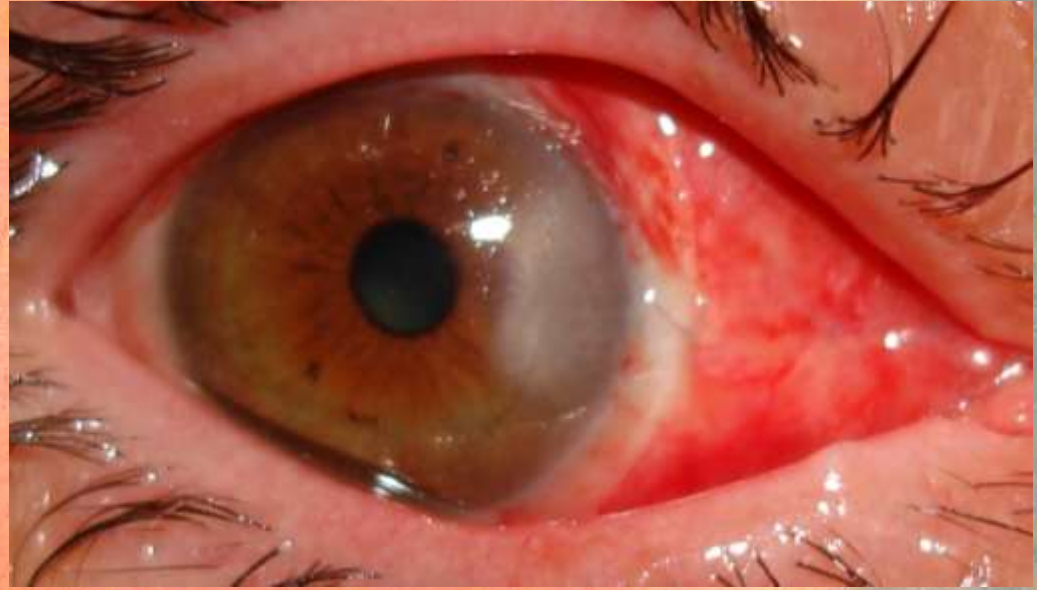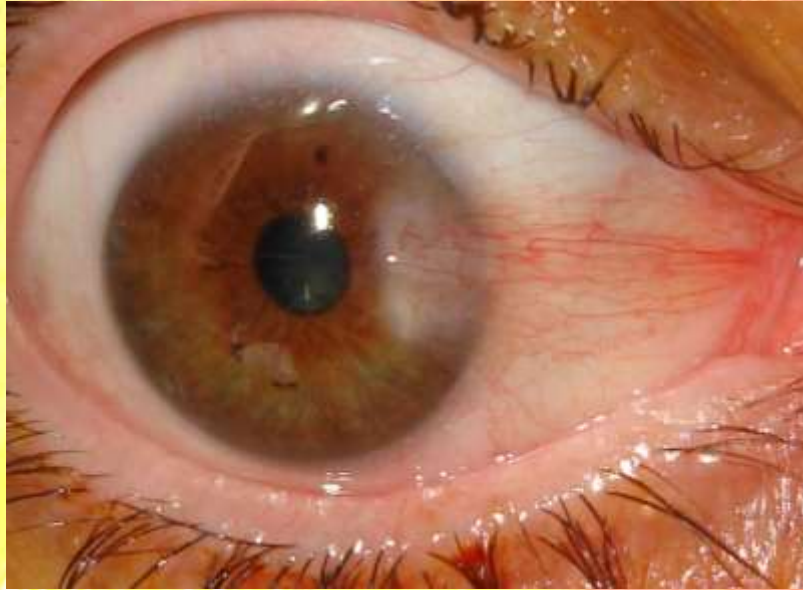
RESULTS, DISCUSSIONS



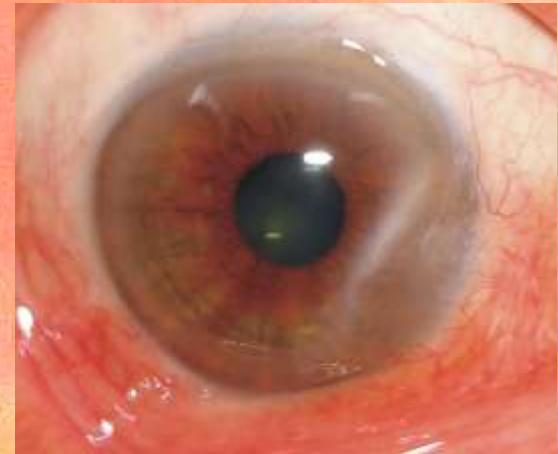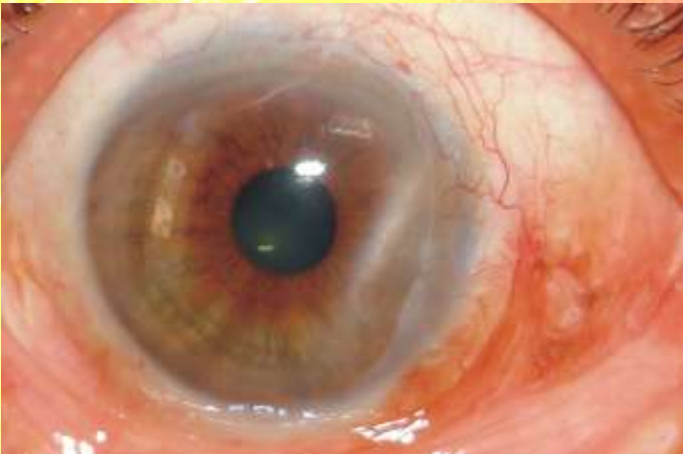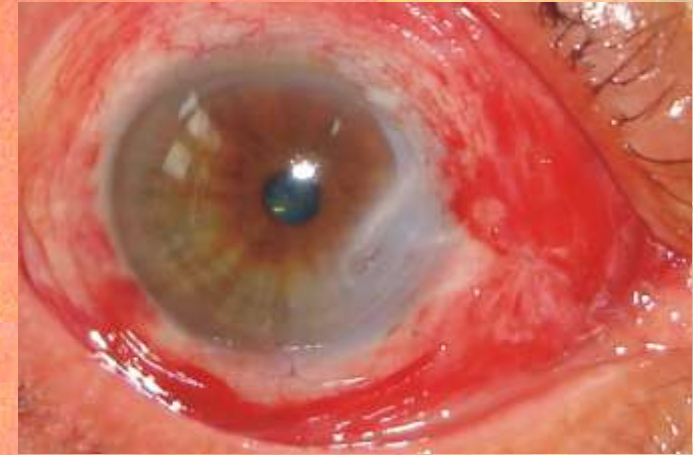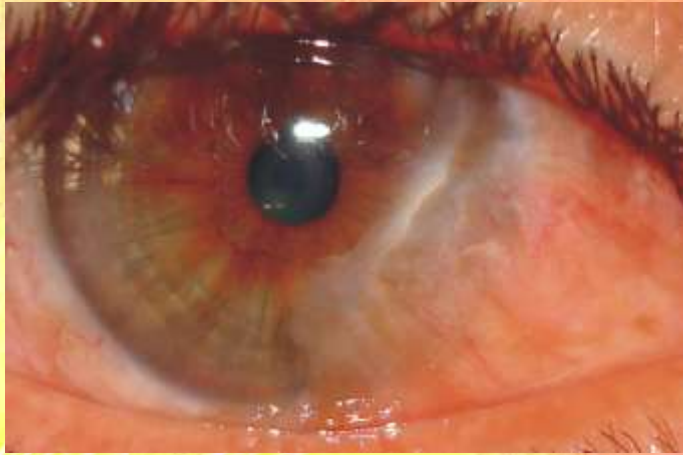TCL & AMT



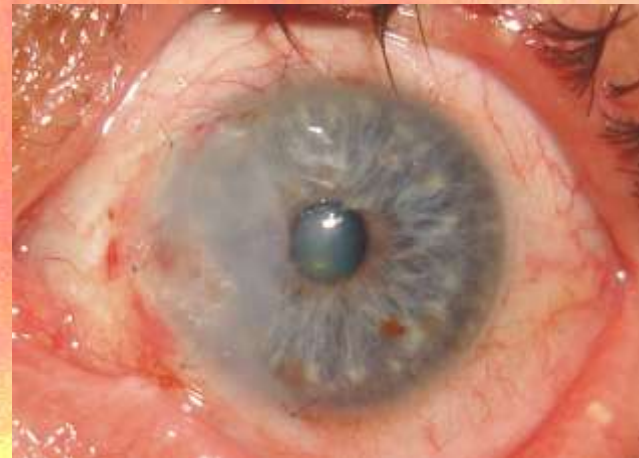
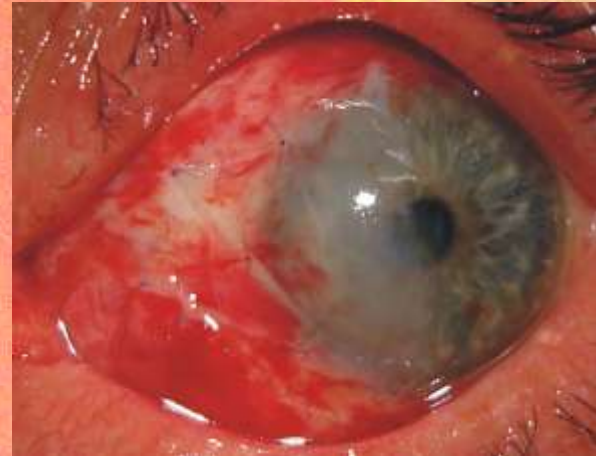
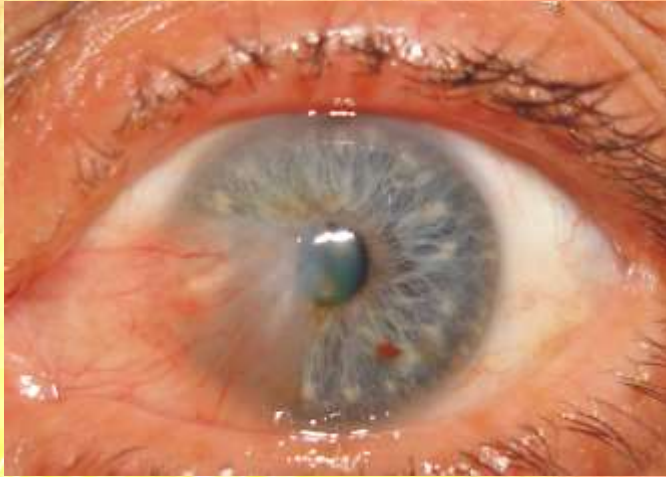
TCL



TCL & AMT

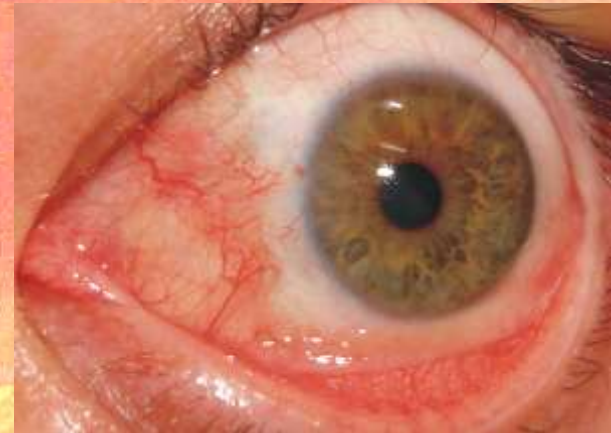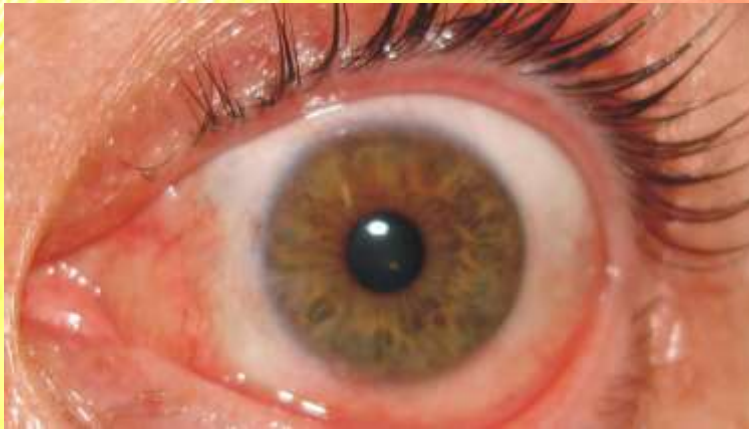

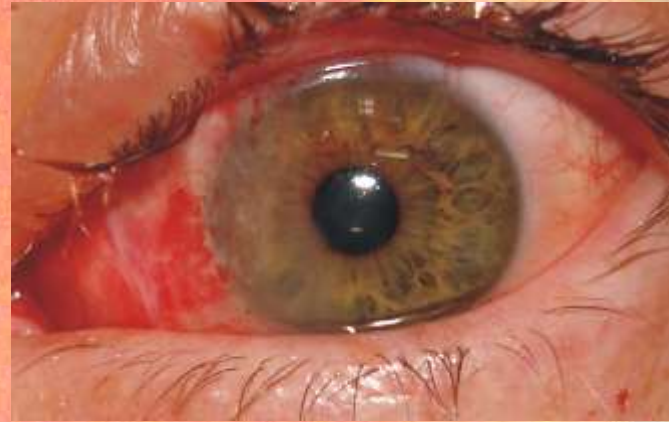
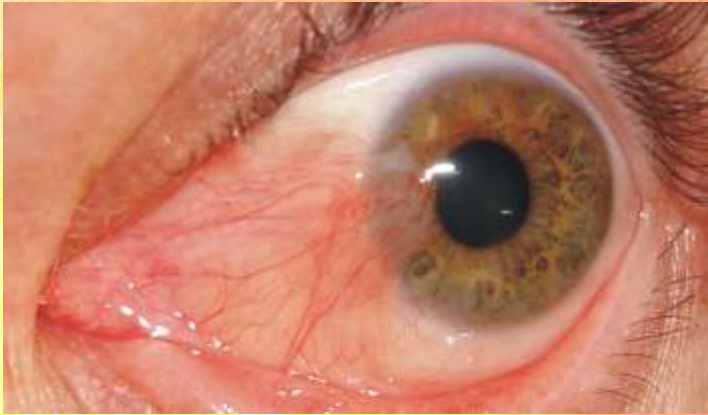TCL & AMT



- TCL – for fixating the AM
AMT – no suture on the clear cornea
- 3-4 points of suture on the limbus
 - free scleral bed

TCL & AMT



CONCLUSIONS

- **Using therapeutic contact lenses in the pterygium surgery (eventually combined with amniotic membrane transplant in certain cases) is a promising option in the management of this unpleasant corneal disease.**
- **Using also avastin the inflammation is diminishing.**
- **TCL + AMT +/- avastin facilitates postoperative recovery and reduces the risk of recurrence after pterygium surgery**
- **The binocularity was possible soon after the surgery**



Thank you!

References

- 1.Ti SE, Tseng TC Management of primary and recurrent pterygium using amniotic membrane transplantation. *Curr Opin Ophthalmol*. 2002 Aug;13(4):204-12
- 2.Küçükerdönmez C, Akova YA, Altinörs DD. Comparison of conjunctival autograft with amniotic membrane transplantation for pterygium surgery: surgical and cosmetic outcome. *Cornea*. 2007 May;26(4):407-13.
- 3.Memarzadeh F, Fahd AK, Shamie N, Chuck RS Comparison of de-epithelialized amniotic membrane transplantation and conjunctival autograft after primary pterygium excision. *Eye*.2008 Jan;22(1):107-12.
- 4.Katircioğlu YA, Altiparmak UE, Duman S.Comparison of three methods for the treatment of pterygium: amniotic membrane graft, conjunctival autograft and conjunctival autograft plus mitomycin C. *Orbit*. 2007 Mar;26(1):5-13
- 5.Luanratanakorn P, Ratanapakorn T, Suwan-Apichon O: Randomized controlled study of conjunctival autograft versus amniotic membrane graft in pterygium excision. *Br J Ophthalmol* 2006;90:1476-1480..
- 6.Hirst LW.Recurrent pterygium surgery using pterygium extended removal followed by extended conjunctival transplant: recurrence rate and cosmesis. *Ophthalmology*. 2009 Jul;116(7):1278-86